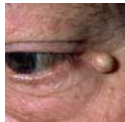
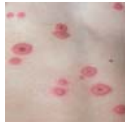
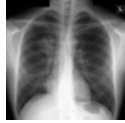
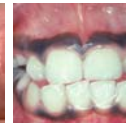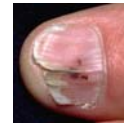Module Overview



VisualDx[®]
visual clinical decision
support software

VisualDx is problem-oriented by design, tailoring patient-relevant diagnoses. With an extensive database of nearly 15,000 images represented in over 800 diagnoses, VisualDx is the comprehensive diagnostic tool for day-to-day clinical diagnosing, emergency preparedness, and medical education.



Take a closer look at our 22 discrete modules including:

Age Specific

- ▶ Neonate/Infant
 - Rash
 - Growth or Lesion
- ▶ Child
 - Rash
 - Growth or Lesion
- ▶ Adult
 - Rash
 - Dark Skin Rash
 - Growth or Lesion
 - Dark Skin Growth or Lesion
- ▶ Elder Adult
 - Rash
 - Growth or Lesion

Respiratory

- ▶ Acute Pulmonary infections

Problem Oriented

- ▶ Fever and Rash
- ▶ Immunocompromised, HIV or AIDS
- ▶ International Travel
- ▶ Drug Eruption
- ▶ Cellulitis DDX

Body Location

- ▶ Oral
- ▶ Nail
- ▶ Female Genital
- ▶ Male Genital

Preparedness

- ▶ Smallpox Vaccination
- ▶ Terrorism Recognition

Age Specific

▶ Neonate/Infant

Rash

Karen McKoy MD, MPH, Lowell A. Goldsmith MD, MPH and Nancy Esterly MD

A vesicular or petechial rash on a newborn may be the first clue to a life-threatening disease. This module brings together nearly 150 diagnoses covering the common and serious dermatologic, genetic, infectious, and inflammatory diseases, illustrated with almost 1,600 photographs.

Growth or Lesion

Karen McKoy MD, Lowell A. Goldsmith MD, MPH and Nancy Esterly MD

The Neonate/Infant Growth or Lesion module can be used to assist in the evaluation of the newborn or infant presenting with a focal or localized process such as a nodule, cyst, or tumor. The module includes nearly 450 images of benign or malignant growths or solitary lesions covering 66 diagnoses.

▶ Child

Rash

Sarah Stein MD, Karen Wiss MD, Sheila Galbraith MD, Dean Morrell MD, Lynn Garfunkel MD, and Nancy Esterly MD

Children presenting with acute or chronic dermatoses, rashes, and exanthems are a daily challenge for clinicians. This module encompasses more than 150 common and serious childhood diseases manifesting with skin findings, illustrated with over 2,200 photographs.

Growth or Lesion

Sarah Stein MD, Karen Wiss MD, Sheila Galbraith MD, Dean Morrell MD, Cynthia Christy MD, and Nancy Esterly MD

The Pediatric Growths or Lesion module is used to evaluate toddlers, children, and teens of all skin types with a common or unusual focal growth or a few localized lesions. This module includes over 40 diagnoses of benign or malignant growths or solitary lesions in children, illustrated with nearly 360 photographs.

▶ Adult

Rash

Lowell A. Goldsmith MD, MPH and Michael Tharp MD

This module includes more than 180 common or serious diseases manifesting with skin findings, illustrated with over 3,000 photographs. This module can be included as part of your normal work up to evaluate adults of all skin types with acute or chronic dermatoses, rashes, and exanthems.

Dark Skin Rash

Paul Kelly MD and Lowell A. Goldsmith MD, MPH

Dark Skin Rash provides an alternative to dermatology atlases and reference tools based solely on Caucasian and other light skinned populations. Over 125 common and serious conditions are included in this visually rich and comprehensive library of nearly 1,500 photographs facilitating rapid and accurate diagnosis of dermatoses, rashes, or exanthems in darkly pigmented adults.

Growth or Lesion

Lowell A. Goldsmith MD, MPH and Michael Tharp MD

The Adult Growth or Lesion module assists you with the diagnosis and management of both common and unusual focal growths and lesions on adults of all skin types. This module includes almost 70 diagnoses of benign or malignant growths or solitary lesions, illustrated with over 900 photographs.

Dark Skin Growth or Lesion

Paul Kelly MD and Lowell A. Goldsmith MD, MPH

Designed specifically to enhance diagnosis of common or rare focal growths and lesions in adults of dark skin types, this module covers nearly 50 diagnoses of benign or malignant growths or solitary lesions in dark skin types. Illustrated with 375 photographs primarily of blacks, but also includes Hispanic, Latino, Indian, Asian, and other patients of color.

► Elder Adult

Rash

Kathryn Bowers MD, Pat Condry MD, and Lowell A. Goldsmith MD, MPH

This module allows rapid, accurate diagnosis of rashes in elder patients and can assist patient management and counseling. This module encompasses 117 common and serious diseases of the elderly manifesting with skin findings, illustrated with nearly 1,400 photographs.

Growth or Lesion

Karen McKoy, MD, MPH, Larry Millikan MD, and Lowell A. Goldsmith MD, MPH

Use this module to evaluate elder adults of all skin types with a common or unusual focal growth or a few localized lesions. This module includes 66 diagnoses of benign or malignant growths or solitary lesions in the elderly, illustrated with more than 650 photographs.

Respiratory

► Acute Pulmonary Infection

Susan Voci MD, Sumanth Rajagopal MD, and William Bonnez MD

Pulmonary infections cannot be diagnosed by radiography alone. The evaluation of the patient with suspected lower respiratory infection combines multiple factors to bring forward a differential diagnosis, resultant empiric treatment, and eventual diagnosis and targeted therapy.

The Acute Pulmonary Infection module covers over 40 bacterial, viral, fungal, and atypical infectious pulmonary diseases, acute pulmonary conditions caused by chemical exposure, and other serious and common acute pulmonary events causing radiographic changes (including emerging and re-emerging infectious diseases such as SARS, avian influenza, and tuberculosis). It's illustrated with more than 430 radiographs, illustrations, and clinical images.

Problem Oriented

▶ Fever and Rash

Art Papier MD and William Van Stoecker MD

The febrile patient with a rash may have a life threatening illness or a simple, benign disease. Rapid, accurate diagnosis can prevent morbidity and reduce false alarms. This module covers more than 125 common and rare infectious, dermatologic, and immunologic diagnoses, including anthrax and other potential biologic agents, illustrated with more than 1,600 photographs.

▶ Immunocompromised, HIV or AIDS

Karen McKoy MD, MPH, and Marvin Turck MD

Use this module to evaluate an immunocompromised patient (e.g., iatrogenic, HIV/AIDS, immunosuppression, or cancer) presenting with skin or mucosal findings. This module covers over 100 diseases in patients of all skin types. It contains more than 1,600 images reflecting the inherent variation of disease expression in immunocompromised patients.

▶ International Travel

Edith Lederman MD and Noah Craft MD, PhD

Designed for use while working abroad or for the evaluation of the patient that has recently traveled or emigrated where there is a clinical suspicion that the diagnosis is travel-related. Search by worldwide geographic location and other clinical findings to improve detection of diseases that are rarely encountered. This module covers over 125 diagnoses, including many infectious diseases, environmental exposures, and common travel-related diagnoses with more than 1,200 images.

▶ Drug Eruption

Michael D. Tharp MD and Neil Shear MD

Common dermatologic problems are often misdiagnosed as drug rashes or, conversely, drug rashes are often not diagnosed or diagnosed late leaving the patient at risk for serious complications. This module includes more than 1,300 photographs covering over 80 diagnoses caused by or predisposed to by medications as well as those diagnoses that are often mistaken for drug eruptions. Use this module for the evaluation of a suspected drug eruption or medication-induced disease.

NEW!

▶ Cellulitis DDX

Karen McKoy MD, MPG, Tara Mahar MD, and Art Papier MD

Focused on diagnosis accuracy for this highly misdiagnosed condition, the Cellulitis module is designed to assist in the consideration of diagnostic possibilities when a patient presents with redness, edema, or warmth of the skin – all typical Cellulitis findings that present similarly in some non-infectious or viral/fungal diseases. This new module includes a total of 70 diagnoses and 1,177 images within the differential diagnosis. A fresh, new user interface quickly steps you through matching patient's findings.

Body Location Specific

▶ Oral Mucosal Lesion

Carl Allen DDS, MSD and Sook-Bin Woo MS, DMD, MMSc

Tailored for dental or primary care practices this module covers nearly 85 oral mucosal diagnoses, including a wide range of benign and malignant neoplasms, infectious processes, inflammatory conditions, and other disorders of the oral cavity. Illustrated with 818 images, this module can be searched by lesion morphology, disease localization and all relevant medical findings.

▶ Nail and Distal Digit

Bertrand Richert MD and Robert Baran MD

This module includes 80 diagnoses covering common and unusual abnormalities, growths, and lesions of the nails and distal digits. Illustrated with over 700 images, this module can be searched by lesional morphology, disease localization and all relevant medical findings.

▶ Female Genital Rash, Growth or Lesion

David Foster MD, Mary Gail Mercurio MD, and Lynne Margesson MD

The Female Genital module includes 61 disease diagnoses including sexually transmitted diseases, benign and malignant lesions and structural diagnoses. Illustrated with over 350 photographs, this body location oriented module may be used to evaluate a vulvar or external female genital rash or growth on women of all skin types, including the immunocompromised.

▶ Male Genital Rash, Growth or Lesion

Lowell A. Goldsmith MD, MPH and Benjamin K. Fisher MD

This module includes nearly 70 male genital disease diagnoses including sexually transmitted diseases, benign and malignant lesions and structural diagnoses, Illustrated with more than 400 photographs, this body-location oriented module may be used to evaluate a male genital rash or growth on men of all skin types, including the immunocompromised.

Preparedness

▶ Smallpox Vaccination

Art Papier MD and Vincent A. Fulginiti MD

This module is a comprehensive visual guide to the normal and adverse events of smallpox vaccination based on the CDC's Smallpox Vaccination and Adverse Events Training web site.

▶ Terrorism Recognition

Tener Goodwin Veenema PhD, MPH, MS, CPNP, Raymond S. Weinstein MD, and Ken Alibek, MD

Covering 56 conditions caused by chemical, biological, or radiological agents, this module includes nearly every Category A, B & C agent as designated by the CDC. With nearly 250 photographs and illustrations and useful, accurate information on each agent, first responders and other clinicians can use this module as a comprehensive training tool as well as point-of-care reference and diagnostic aid.



Interested?

sales@logicalimages.com

Support!

support@logicalimages.com

Or call us at:

800.357.7611

We welcome your comments!



3445 Winton Place, Suite 240
Rochester, NY 14623